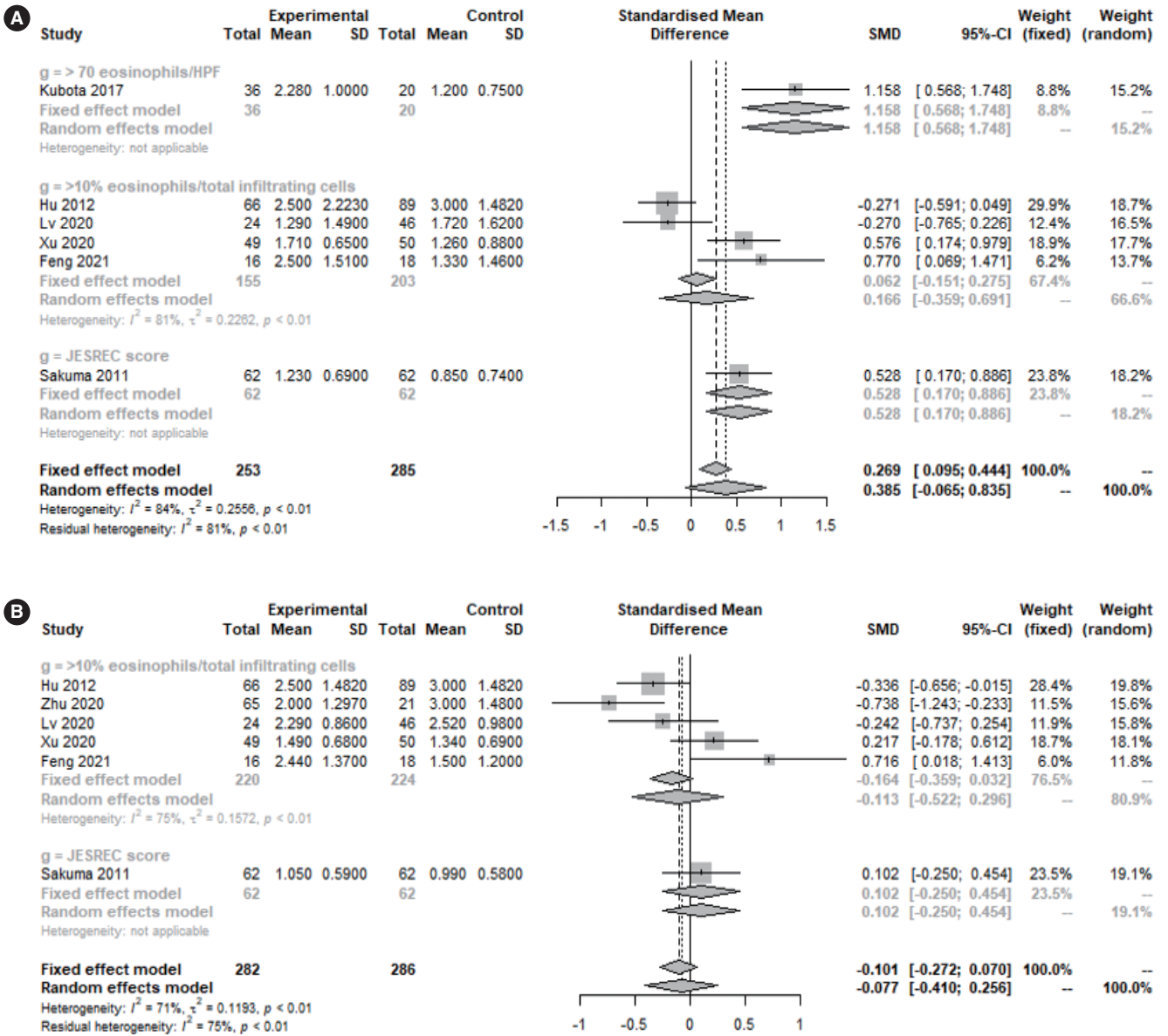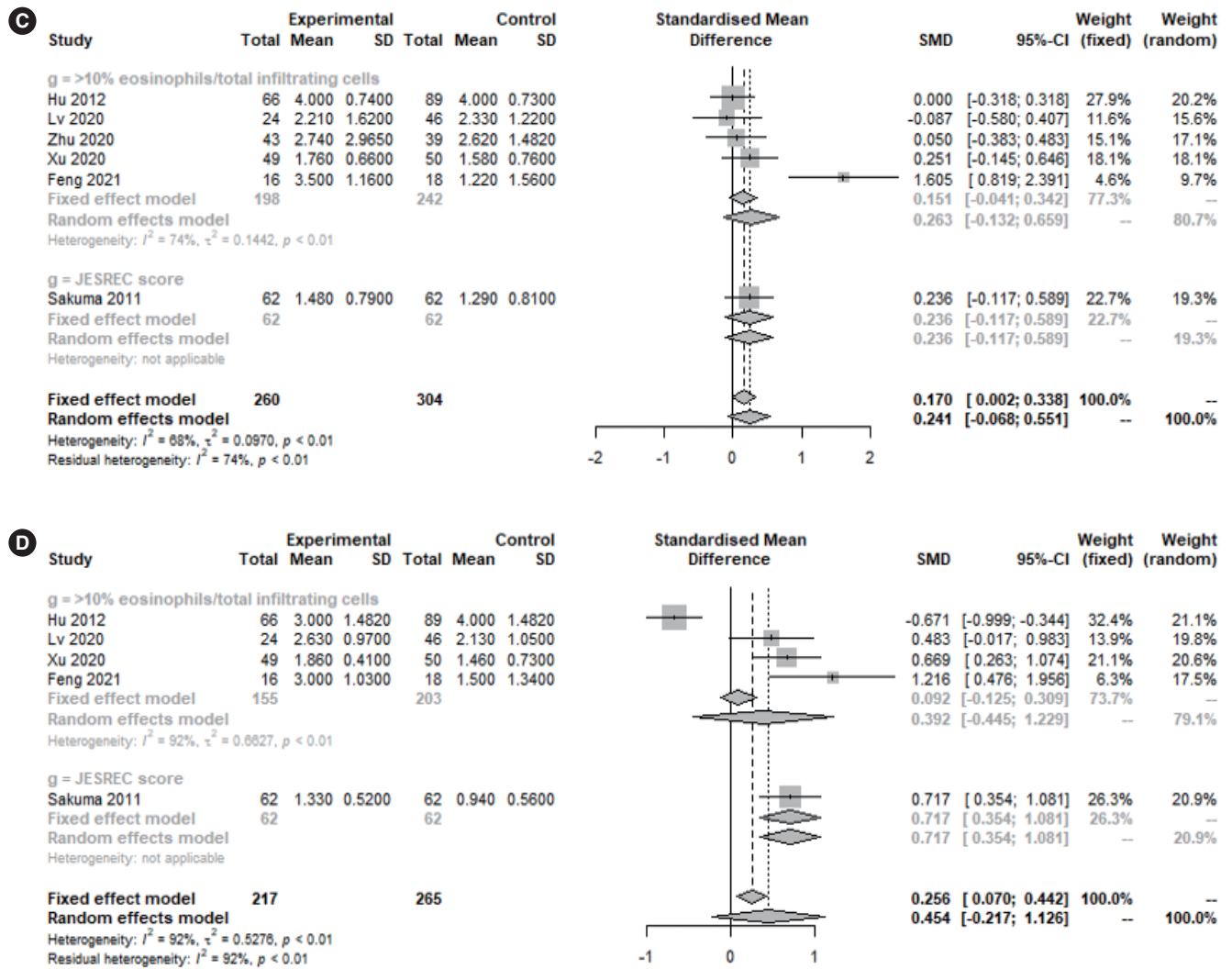


Supplementary Fig. 2. Sinus opacification scores in eosinophilic and non-eosinophilic chronic rhinosinusitis. (A) Frontal sinus. (B) Maxillary sinus. (Continued to the next page)



Supplementary Fig. 2. (Continued) (C) Ostiomeatal unit. (D) Posterior ethmoid sinus. SD, standard deviation; SMD, standardized mean difference; CI, confidence interval; JESREC, Japanese Epidemiological Survey of Refractory Eosinophilic Chronic Rhinosinusitis.